

# Esophageal leiomyoma. Experience with nine surgical patients

Giovanna Mainieri-Breedy<sup>1</sup>, José-Alberto Mainieri-Hidalgo<sup>2</sup>

## Abstract

**Aim:** The aim of this study is to inform the experience acquired operating esophageal leiomyoma in the Thoracic Surgery Department of the Hospital Calderón Guardia.

**Methods:** Fourteen patients with submucosal esophageal tumors were referred to the Thoracic Surgery Department at Hospital Calderón Guardia during the twelve-year period comprised between 1999 and 2011. The approach for four asymptomatic patients with a small mass was observation, and the remaining ten underwent surgical procedures to confirm the histologic diagnosis of Leiomyoma. With authorization provided by the Ethical Committee of the Hospital, clinical records were reviewed, considering personal characteristics, symptoms, methods for diagnosis, surgical treatment and follow-up for the patients involved.

**Results:** Ten surgical patients were analyzed, eight were male and two female. Their age ranged from 38 to 71 years, with an average of 56 years. Their primary complaint was dysphagia. In three cases the tumor findings were incidental, while performing an upper endoscopy for digestive symptoms. In all cases the method used for detection was an upper endoscopy describing either a submucosal tumor or an extrinsic compression of the esophageal wall. The endoscopic ultrasound correlated in all cases that the tumor originated from the fourth layer of the esophagus, compatible with leiomyoma. In two cases the possibility of malignancy was questioned due to the dimensions of the lesion. Nine patients were operated through a thoracotomy and one through a laparotomy. In 7 cases enucleating was successful without perforation of the mucosa. In two patients partial esophagectomy with anastomosis and diaphragmatic patch was performed. In an exceptional case, the tumor extended from the cervical esophagus to the esophagogastric union, so a total esophagectomy was done with a gastric interposition. There was no mortality reported. One patient complicated with an small anastomotic leak that was resolved without intervention. Two patients had respiratory problems that prolonged their hospital stay. In the 12 years and 8 months of follow up, there has not been any relapse or complication.

**Conclusion:** The surgery of submucosal esophageal tumors can be performed without mayor morbidity if there is an adequate preoperative evaluation and Management is made. None of the cases of this series had complications or recurrence to the date the study was made.

**Key words:** esophageal leiomyoma, esophagus, tumors, endoscopic ultrasound.

**Date Received:** June 20th, 2011

**Date Accepted:** May 28th, 2012

Thoracic Surgery Department,  
Dr. Rafael Ángel Calderón  
Guardia, Caja Costarricense de  
Seguro Social.

Author's Memberships: <sup>1</sup>Gastric  
Cancer Early Detection Center.  
Hospital Max Peralta, Caja  
Costarricense de Seguro Social.  
<sup>2</sup> Thoracic Surgery Department,  
Hospital Calderón Guardia, Caja  
Costarricense de Seguro Social.

**Abbreviations:** FNAB, fine  
needle aspiration biopsy;  
GIST, Gastrointestinal stromal  
tumor; CAT scan, computed  
axial tomography; T2, measure  
on magnetic resonance that  
indicates an increased echo time  
and a greater repetition time;  
EUS, endoscopic ultrasound.

**Correspondence:**  
mainierijose@hotmail.com

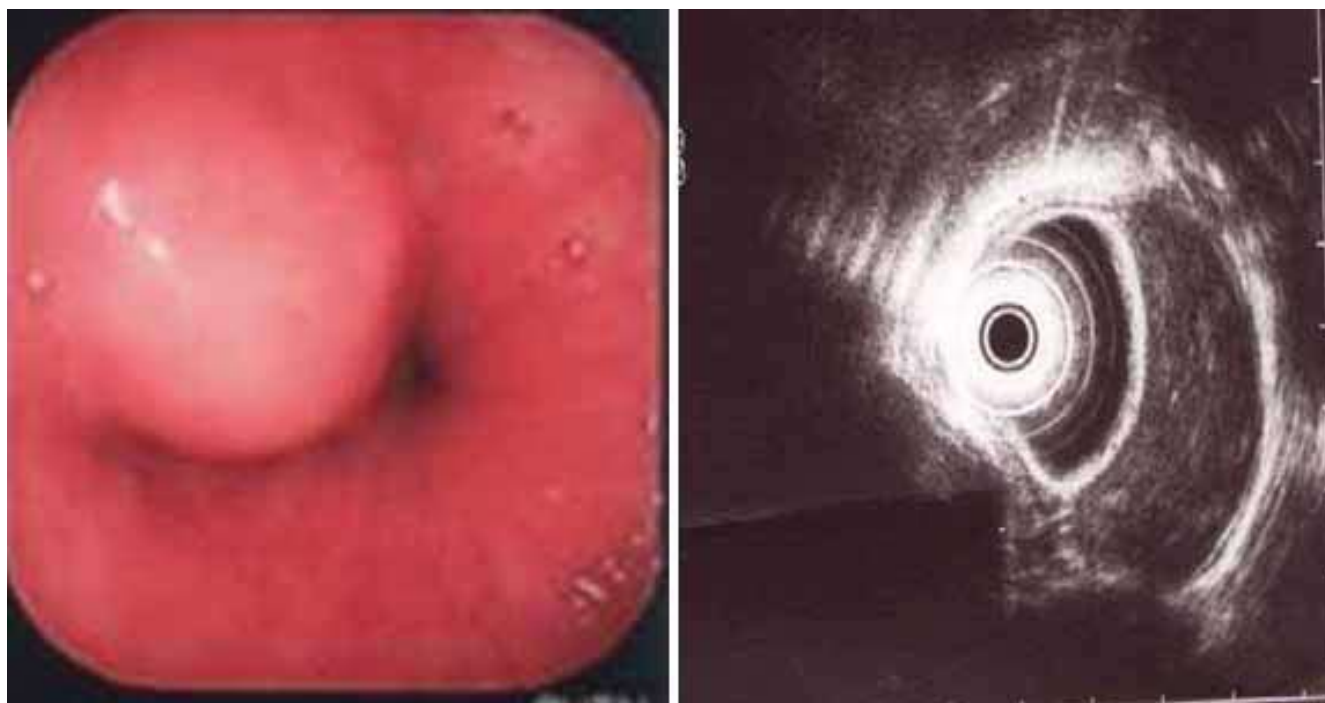


Figure 1 a. Endoscopic image of a submucosal leiomyoma and b. endoscopic ultrasound of an esophageal leiomyoma.

Benign tumors of the esophagus are rare, constituting less than 1% of neoplasias of this organ. Leiomyoma is the most common, occurring in about two thirds of cases, representing 10% of gastrointestinal leiomyomas. The rest are cysts and polyps. The overall incidence of esophageal leiomyomas is 8 to 43 per 10,000 cases, in a series of autopsies. 90% are diagnosed between the ages of 20 and 70 years old, and are twice as common in men than in women (2:1).<sup>1</sup>

Leiomyomas are mesenchymal tumors that grow intramurally. Mostly located in the distal third (60%), followed by the middle (33%) and upper third of the esophagus (7%).<sup>2</sup> Histologically, the tumors are comprised of smooth muscle tangles, well-demarcated by adjacent tissue or by a connective tissue capsule. Macroscopically, well-defined masses are visualized in the esophageal wall; cut surface is solid with a grayish white color. The majority occur as single lesions, of less than 5cm in diameter, but 5% may be multiple, especially patients with Alport's Syndrome. Large tumors present themselves as posterior mediastinal masses that compressed adjacent organs and may be confused with neoplasias.<sup>3</sup> The differential diagnosis is made with esophageal cancer, gastrointestinal stromal tumors (GIST) and other benign esophageal tumors.<sup>4</sup> Leiomyomatosis is characterized by diffuse hypertrophy of all muscle layers of the esophagus and the presence of lymphocytic and plasma cell infiltration; usually accompanied by leiomyomas elsewhere, neuropathy, hearing problems, myopia or

astigmatism (Alport's Syndrome). The management in these cases consists of esophageal resection and replacement with the stomach or the colon.<sup>5,7</sup>

When small (less than 5cm), manifestation of symptoms is rare. Their growth is usually slow and, as they grow, symptoms are intermittent and progressive similar to those of esophageal cancer, such as dysphagia, retrosternal discomfort, chest pain, weight loss, esophageal obstruction and regurgitation. The size to produce symptoms is usually greater than 6 or 8cm.<sup>8</sup>

The diagnostic methods commonly used are: esophagogram, endoscopy, endoscopic ultrasound (EUS), and computed axial tomography (CAT scan). On esophagogram, the classic appearance is a filling defect, smooth and concave border in the underlying normal mucosa.<sup>1,3</sup> By endoscopy, a mobile submucosal lesion can be seen, with an intact mucosa. If a leiomyoma is suspected, biopsy by any method should be avoided, the tearing of the mucosa difficult extramucosal resection (enucleation). If ulceration is present or there is suspicion of malignancy, a biopsy should be performed; a useful method is fine needle aspiration biopsy (FNAB). If a biopsy is performed, it is recommended to postpone surgery at least 2 weeks, to allow the esophageal mucosa to heal and diminished the risk of perforation.<sup>9</sup> Endoscopic ultrasound, demonstrate a homogeneous region of juxtaposed hypoechogenicity with the overlying mucosa. The radiologic findings of an

esophageal leiomyoma described it as a marginal mass, smooth, round or lobulated, projecting to one or both sides of the mediastinum, along the course of the esophagus. The CAT scan disclosed homogenous intramural mass, round or ovoid; or a thickening of the esophageal wall, without alterations in the mediastinal fat. Magnetic resonance imaging with T2, emit an iso-intense signals, while esophageal cancer emit high intensity signals.<sup>2,3</sup>

Small and asymptomatic submucosal tumors may be periodically monitored. The indication for resection is based on symptoms, size (>5cm), evidence of growth, ulceration or malignant degeneration, but this is rare.<sup>10</sup> The recommended method of resection is enucleation, preserving the integrity of the mucosa. When the tumor is larger than 8cm, when adhered to the mucosa, or when there has been an extensive tearing during dissection, it may be necessary to remove part of the esophagus. The concomitant use of endoscopy helps to locate the lesion and detect perforations in the esophageal wall.<sup>11</sup> In 1992, Everitt reported the first successful thoracoscopic esophageal enucleation, and in 2010, Wang et al reported<sup>12-14</sup> thoracoscopic resection of 42 esophageal leiomyomas or GISTs, with diameters up to 5cm. Thus, concluding that endoscopic surgery can be performed with good results, although there is a greater risk for perforation when comparing to conventional surgery.<sup>15</sup>

Mortality of a thoracotomy excision is 0-1.3%,<sup>2</sup> and the described morbidity includes pain, atelectasia and pneumonia. The follow up consists in periodic esophagograms and endoscopies to detect recurrences.

The goal of this paper is to review the cases treated in the Department of Thoracic Surgery of the Hospital Calderón Guardia, which is a reference center of this condition, in order to analyze and inform particular characteristics of patients with leiomyomas, detection tests and methods; and the results of surgical removal.

---

## Materials and methodology

---

Upon review and approval of the protocol by the Ethics and Research Committee of the Hospital, we review the clinical records of fourteen patients included in the database of the Department of Thoracic Surgery, which were evaluated as esophageal leiomyomas during the period 1999 and 2011, analyzing the patient's characteristics, clinical detection methods and tests, performed surgery and postoperative control. Four asymptomatic patients with suspected leiomyomas were not included in the review and continue control in the Gastroenterology Department.

---

## Results

---

During the studied period, 10 patients with esophageal leiomyomas underwent surgery. Ages ranged from 38 to 71 years old, with an average of 56. In relation to gender, eight were men and two were women. Seven cases were detected at the Cancer Early Detection Center of the Hospital Max Peralta.

The detection distribution per year is shown in table 1, and corresponds to less than one case per year, in a third level national reference center, attending a little more than a third of the adult population.

Of ten patients, seven consulted for dysphagia, and in three cases the finding was incidental, while performing an endoscopy for upper gastrointestinal symptoms. The detection method in all cases was with endoscopy, describing the presence of a well-defined submucosal lesion or an extrinsic compression of the esophageal wall, with integrity of the mucosa (Fig. 1a). In one occasion, an ulceration of the mucosa was described.

The esophagogram was performed in five cases; in two cases an extrinsic compression of the esophageal wall was described; in another two a lesion that diminished the diameter of the lumen of the esophagus, of origin to be determined, and in one case, a submucosal tumor (Fig. 2a).

In nine of ten cases, the endoscopic ultrasound described a lesion that emerged from the fourth layer, with similar size as described by the pathologist in the surgical specimen. In one case, the study was not performed. The diagnosis by an ultrasonographer was leiomyoma in seven cases, and leiomyoma or leiomyosarcoma in 2 cases (Fig. 1b).

In one case, the growth was towards the lumen, reaching a great size, seen in a CAT scan as a posterior mediastinal tumor (Fig. 2b).

Surgical treatment in seven cases was enucleation of the tumor, maintaining the integrity of the mucosal layer. Two patients underwent partial esophagectomy with end-to-end anastomosis and diaphragmatic patch; and in the case of a leiomyoma that extended from the neck to the cardioesophageal junction, a total esophagectomy with gastric ascension and cervical esophagogastric anastomosis was performed.

The location of the lesions, in one case was in the proximal third, in an intrathoracic position; eight were located in the middle third, all underwent a right thoracotomy; and one was in the distal third, and was accessed by laparotomy.

**Table 1.** Distribution per year of resected esophageal leiomyomas at Hospital Calderón Guardia

Year	Number Cases
1999	2
2004	1
2005	1
2007	3
2008	1
2010	1
2011	1
Total	10

No patient died. A patient with esophagectomy presented a small anastomosis leakage, described in an esophagogram as a diverticuli at the level of the anastomosis, which did not require reintervention. Two patients developed respiratory infections that prolonged their post operative stay. One complained of prolonged pain in the dermatome of the surgical approach, requiring infiltrations and psychological support.

No recurrences or complications have been presented and the follow up of the patients varies from 8 months to 12 years.<sup>14</sup>

## Discussion

Esophageal leiomyoma is an unfrequented tumor, and over a 12 years study, only ten were excised, in a higher national reference center. The main symptom, same as the majority of esophageal diseases, was dysphagia, so it does not direct to a specific diagnosis. However, the esophagogram and the endoscopy are highly suggestive, with a classic image shown on figures 1 and 2. It is relevant to point out the importance of not performing any type of biopsy in resectable tumors, so it can be excised extramurally, such as in the seven cases in which esophagectomy was not required.

Endoscopic ultrasound performed by an experienced operator, helped to confirm the origin of the tumor in the muscle layer of the esophagus, such as in nine cases in the review, performed by the Cancer Early Detection Center in Cartago. A generated doubt in three cases when the lesion was too large was the possible malignancy; in the department, no cases have been described of esophageal leiomyosarcoma, this lesion is much rarer.

The tendency of the tumor is to compress the esophageal lumen and cause obstruction, manifesting as dysphagia, and this was the surgical indication in seven patients. In three cases, the tumor grew outside the wall; one of them reach a size of approximately 8cm and in CAT scan was presented as a posterior mediastinal tumor.

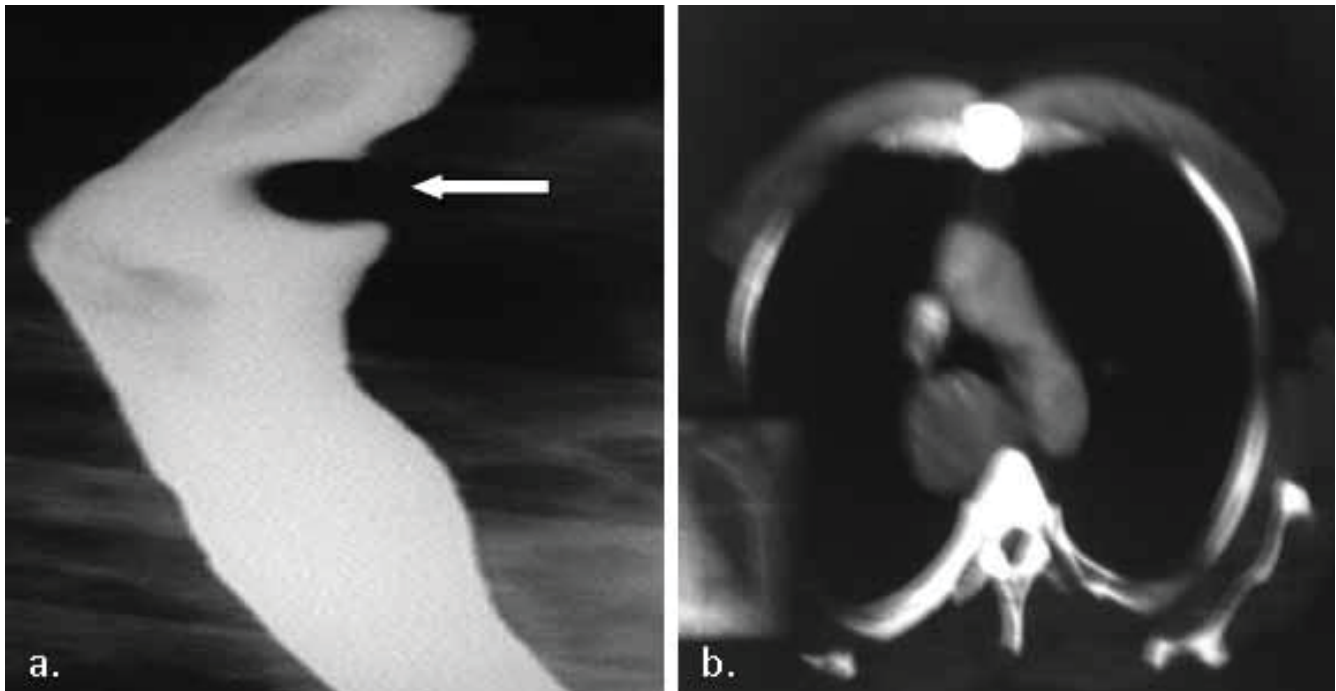


Figure 2 a. Esophagogram image of an esophageal leiomyoma b. a large sized posterior mediastinal esophageal leiomyoma on a computed axial tomography.

The enucleation was performed in seven cases, without complications. The esophagectomy was performed in three cases, associated in one case with a small anastomosis leakage with no further morbidity, and two patients presented respiratory infections, and were discharged in the tenth and twelfth postoperative day, in good conditions.

We conclude that surgery of submucosal tumors of the esophagus, when studied and handled properly preoperatively, surgery can be performed without increased morbidity, and in none of the cases studied were complications or recurrences to date of the review.

---

## References

---

1. Punpale A, Rangole A, Bhambhani N, Karimundackal G, Desai N, de Souza A, Pramesh CS, Jambhekar N, Mistry R. Leiomyoma of Esophagus. *Ann Thorac Cardiovasc Surg* 2007; 13:78-81.
2. Saleh W, Bamosa A, Al-Mutairi H, Al-Kattan K. Thoracoscopic enucleation of esophageal leiomyoma in patient with MEN I syndrome. *Ann Thoracic Med* 2010; 5:47-49.
3. Yang P.S., Lee K.S., Lee S.J., Kim T.S., Choo I.W., Shim Y.M., Kim K., Kim Y. Esophageal Leiomyoma: Radiologic Findings in 12 Patients. *Korean J Radiol* 2001; 2:132-137.
4. Loviscek L.F., Yun J.H., Park Y.S., Chiari A., Grillo C., Cenoz M.C. Leiomioma de esófago. *Cir Esp*. 2009; 85: 147-51.
5. Boran C., Sengul N., Balaban Y.H., Gürel S. Multinodular leiomyoma of the esophagus with internodular hydropic degeneration and bulbous serosal protrusions similar to cotyledonoid uterine leiomyoma. *Diseases of the Esophagus* 2007; 20:187-189.
6. Okugawa Y., Mohri Y., Toiyama Y., Yokoe T., Ohi M., Tanaka K., Uchida K., Shiraishi T., Kusunoki M. Multiple Solitary Leiomyomas in the Esophagus: Report of a Case. *Surg Today*. 2011; 41: 563-567.
7. Obuchi T., Sasaki A., Nitta H., Koeda K., Ikeda K., Wakabayashi G. Minimally invasive surgical enucleation for esophageal leiomyoma: report of seven cases. *Diseases of the Esophagus*. 2010; 23: E1-E4.
8. Asteriou C., Konstantinou D., Lalountas M., Kleontas A., Setzis K., Zafiriou G., Barbetakis N. Nine year experience in surgical approach of leiomyomatosis of esophagus. *World J Surg Oncol* 2009; 7: 102.
9. Jiang G., Zhao H., Yang F., Li J., Li Y., Liu Y., Lui J., Wang J. Thoracoscopic enucleation of esophageal leiomyoma: a retrospective study on 40 cases. *Diseases of the Esophagus*. 2009; 22: 279-283.
10. Schorlemmer G., Battaglini J., Murria G. The Cervical Approach to Esophageal Leiomyomas. *Ann Thoracic Surg* 1983; 35: 469-472.
11. Li Z.G., Chen H.Z., Jin H., Yang L.X., Xu Z.Y., Liu F., Yao F. Surgical treatment of esophageal leiomyoma located near or at the esophagogastric junction via a Thoracoscopic approach. *Diseases of the Esophagus* 2009; 22: 185-189.
12. Zaninotto G., Portale G., Costantini M., Rizzetto C., Salvador R., Rampado S., Pennelli G., Ancona E. Minimally invasive enucleation of esophageal leiomyoma. *Surg Endosc* 2006; 20: 1904-1908.
13. Dapri G., Himpens J., Ntounda R., Alard S., Dereeper E., Cadiere G.B. Enucleation of a leiomyoma of the mid-esophagus through a right thoracoscopy with the patient in prone position. *Surg Endosc*. 2010; 24: 215-218.
14. Wang L., Fan C.Q., Ren W., Zhang X., Li Y.H., Zhao X.Y. Endoscopic dissection of large endogenous myogenic tumors in the esophagus and stomach is safe and feasible: A report of 42 cases. *Scandinavian Journal of Gastroenterology*. 2010; 46: 627-633.
15. DeUgarte D., Teitelbaum D., Hirschl R., Geiger J.D. Robotic Extirpation of Complex Massive Esophageal Leiomyoma. *J Laparoendoscopic & Advanced Surgical Techniques*. 2008; 18: 286-289.
16. Slessor A.A.P., Shaw I. A Large Esophageal Leiomyoma. *International Journal of Surgical Pathology* 2009; 17: 401.
17. Gupta V., Lal A., Sinha S.K., Nada R., Gupta N.M. Leiomyomatosis of the Esophagus: Experience over a Decade. *J Gastrointest Surg*. 2009; 13: 206-211.